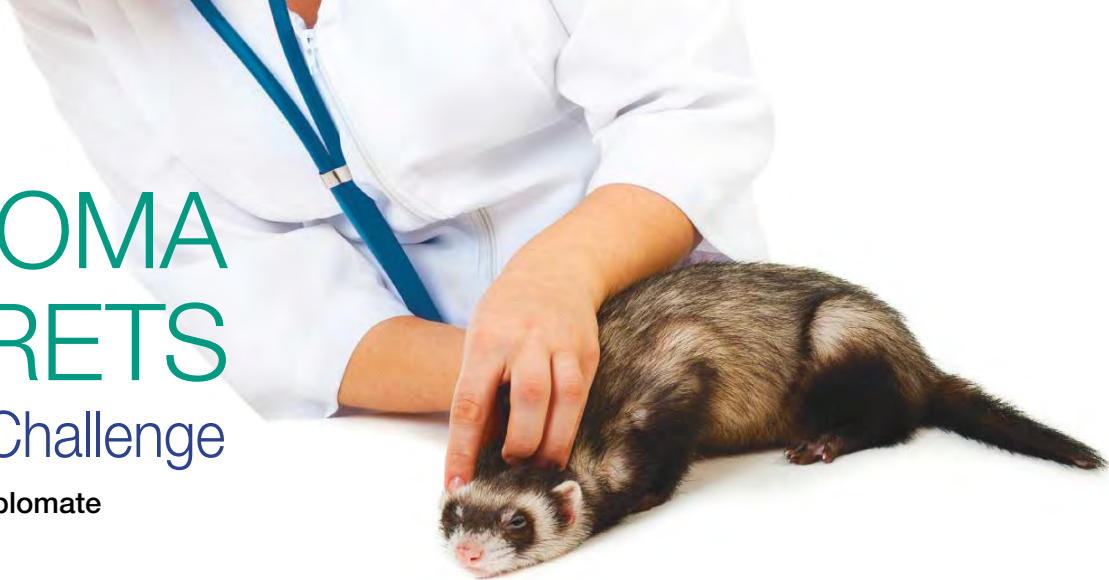

# LYMPHOMA IN FERRETS

## A Diagnostic Challenge

Natalie Antinoff, DVM, Diplomate  
ABVP (Avian Practice)



As one of the most common diseases of ferrets, we expect lymphoma to be easy to diagnose; yet it is a diagnostic challenge in many cases. It is tempting to compare the clinical presentation to that of dogs or cats, but in reality there are as many variations as there are similarities. This disease can occur anywhere in the body and clinical presentation and diagnostic results may vary, leading to an incorrect diagnosis.

The intent of this article is to identify common clinical features of ferrets with lymphoma and to aid practitioners in correctly diagnosing this disease.

### PATHOPHYSIOLOGY

Lymphoma in ferrets has a wide variety of clinical presentations.

- It may affect a single lymph node, single organ, multiple organs, and/or blood and bone marrow.
- As a disease of the hematopoietic system, it is commonly associated with the lymphatic system and associated areas, but may occur anywhere, including aberrant sites, such as the eyes, heart, or kidneys.<sup>1-3</sup>
- Cluster outbreaks have been reported, and a retroviral etiology has been proposed for some cases.<sup>4</sup>
- To date, a viral agent has not been identified and associations with Aleutian disease and feline leukemia virus have both been disproven.<sup>2,5,6</sup>

### FORMS OF LYMPHOMA

Early literature states that there are 2 primary forms of lymphoma: a juvenile form characterized by acute onset, lymphocytosis, and multicentric distribution, and an adult

form characterized by slower onset and abdominal organ involvement. Presence of blast cells in those studies was limited to juvenile ferrets.<sup>1,2,7</sup>

More recent studies contradict some of these findings. Two recent retrospective studies found a lymphoblastic form of lymphoma occurring in ferrets of all ages.<sup>8,9</sup> Lymphocytosis and peripheral lymphadenopathy were rare findings overall.<sup>9</sup> This may represent a natural shift in the disease, population shift, regional variation, or many factors yet unidentified.

Regardless, at this time, age of ferrets at time of diagnosis can no longer be considered a reliable indicator of type or extent of disease, nor can it be a prognostic indicator.

### CLINICAL FINDINGS

#### Clinical Signs

Clinical signs of lymphoma in ferrets are nonspecific and usually related to the organ or system affected. Common clinical presentations include:

- Lethargy
- Inappetence or anorexia
- Diarrhea
- Weakness
- Respiratory difficulty.

Some ferrets may have no clinical signs; in my practice, 24% of ferrets diagnosed with lymphoma have been asymptomatic.

#### Physical Examination

Because lymphoma may occur in a single organ or multiple systems, physical examination findings vary greatly, depending on the location and extent of disease. Pale mucous membranes, weakness, abdominal masses, intes-

### ARTICLE OVERVIEW: CRITICAL POINTS

- **There is no universal or classic presentation of lymphoma in ferrets.**
- The blast form of lymphoma is not limited to juvenile ferrets as previously believed.
- Age cannot be considered a reliable indicator of disease type, extent, or prognosis.
- **Anemia is the most common hematologic abnormality.**
- Lymphocytosis and peripheral lymphadenopathy are not common clinical findings.
- Mesenteric lymphadenopathy is a common finding in lymphoma but is nonspecific and can be caused by many other diseases.
- **Cytology or histopathology is the only way to diagnosis lymphoma.**
- Previous or concurrent administration of steroids can interfere with diagnostic testing.
- **Grade, stage, and phenotype should be determined for all ferrets diagnosed with lymphoma.**
- There are currently no published studies to evaluate prognostic indicators for different types of disease or treatment protocols.

tinal thickening, diarrhea, respiratory abnormalities, or other nonspecific signs may be present.

Cutaneous epitheliotropic lymphoma may present differently than other forms of lymphoma. There may be erythema and/or swelling of the feet. Although prognosis is good if solitary lesions can be excised, these more commonly occur as multiple lesions or diffuse disease of the feet, and therapy may be unrewarding.<sup>10,11</sup>

## DIAGNOSTIC EVALUATION

### Hematology

Anemia is the most common clinical abnormality identified with lymphoma.<sup>9</sup> In one retrospective study, a total of 22/27 ferrets with lymphoma (81%) had some degree of anemia.

- In that study, 10/27 ferrets had anemia classified as severe (hematocrit, < 25%), 8/27 were moderate (hematocrit, 26%–35%), and 4/27 had mild anemia (hematocrit, 36%–42%).
- All anemias were nonregenerative.
- Lymphocytosis was only present in 2/27 cases (< 8%); both were determined to have leukemia.
- Neutropenia was identified more commonly than lymphocytosis (5/27 ferrets), and thrombocytopenia was present in 2/27 ferrets.
- Lymphocytosis and/or lymphopenia are not common and are not reliable indicators of lymphoma in ferrets.

### Serum Biochemical Profile

There is no consistent biochemical marker for lymphoma. Biochemical abnormalities are most often related to the organ system affected.

- Hyperproteinemia and hyperglobulinemia have been found in some ferrets with T-cell lymphoma.
- Hypoalbuminemia has been identified in some ferrets with small intestinal disease.<sup>9</sup>
- Hypercalcemia is very rare, occurring in < 10% of affected ferrets in one study.<sup>9</sup>

### Bone Marrow Collection

Bone marrow collection is indicated whenever there is an abnormality suggestive of lymphoma in the hematologic profile. Generally, this is in cases of lymphocytosis, leukopenia, or nonregenerative anemia of unclear etiology. Bone marrow can be collected in standard fashion from the humerus or femur, or a core bone biopsy can be obtained. This technique has been described in other literature.<sup>12,13</sup>

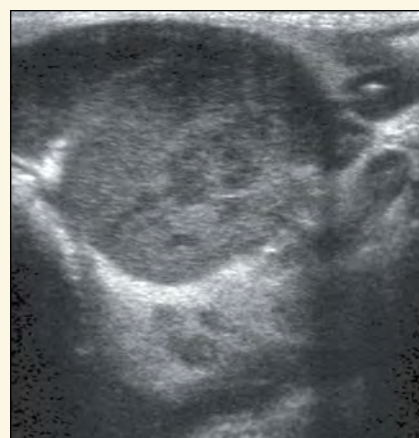## Diagnostic Imaging

### Radiography

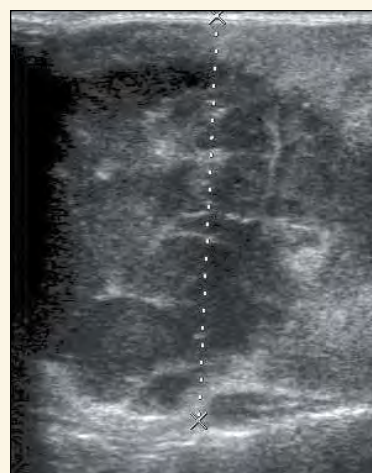
Radiographic abnormalities that may lead the clinician to suspect lymphoma include:

- Mediastinal or thoracic nodal masses
- Pleural effusion
- Abdominal masses.

However, because these findings may be caused by a variety of diseases, additional diagnostic sampling is indicated. While radiographs are necessary, they should be considered screening or supportive tests.



**Figure 1.** Ultrasound image of the spleen of a ferret with multifocal nodular hyper-echoic and hypoechoic regions, showing infiltrative disease eventually diagnosed as lymphoma.



**Figure 2.** Ultrasound appearance of a markedly enlarged mesenteric lymph node with cavitation in a ferret with lymphoma; note that not all ferrets with enlarged mesenteric lymph nodes have lymphoma—other causes should always be considered.

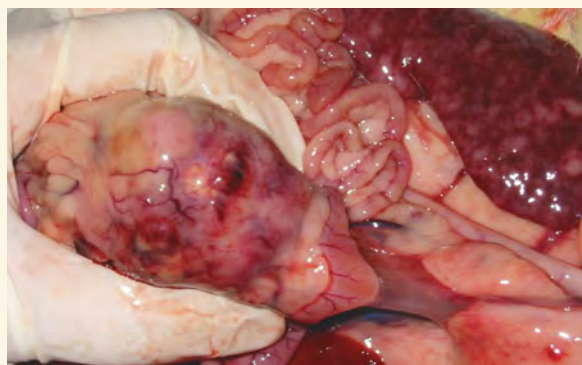
### Ultrasonography

Ultrasonography may provide additional information and should be performed as part of the staging process.

- Evidence of hepatic or splenic infiltrate may provide a source for sampling (**Figure 1**).
- Mediastinal and intestinal masses can also be identified and sampled.
- Atypical sites, such as ocular and retrobulbar lymphoma, can be assessed and sampled, if needed.

Mesenteric lymphadenopathy is commonly present in lymphoma (**Figure 2**). However, it is important to note that mesenteric lymph nodes of normal ferrets may appear relatively larger than expected for their body size and, therefore, are not necessarily indicative of disease. Sonographic characteristics of normal mesenteric lymph nodes of ferrets have been described.<sup>14</sup>

In addition, ferrets may develop intestinal lymphadenopathy in response to a wide variety of other diseases; this finding should not be considered diagnostic for lymphoma. In the author's practice, almost all ferrets with lymphoma had mesenteric lymphadenopathy, but only a small number of ferrets with lymphadenopathy had lymphoma.



**Figure 3.** Necropsy photograph demonstrating mesenteric lymph node enlargement and infiltrative splenic lymphoma in a ferret.

### Advanced Imaging

Advanced imaging, such as computed tomography and magnetic resonance imaging, may become more useful in identifying and staging lymphoma as they become more clinically available. These tools are the most reliable way to diagnose spinal and central nervous system lymphoma.<sup>15</sup>

### Cytology & Pathology

**Cytology or histopathology is the only definitive way to diagnose lymphoma.**

### Fine-Needle Aspiration

- Fine-needle aspirates are performed as in other species, but it is imperative that a pathologist experienced with ferrets performs the cytologic evaluation.
- Reactive lymph nodes may mistakenly be classified as lymphoma and neoplastic nodes may be misclassified as reactive simply due to small sample size and artifacts obtained by aspirate.

### Tissue Biopsy

- Whenever possible, tissue biopsy is preferable to fine-needle aspirate.
- If peripheral lymphadenopathy is present, excision of a node is simple and diagnostic.
- The popliteal node, if enlarged, is easily removed.
- Removal of the spleen is not recommended as a diagnostic modality (and rarely recommended as a therapeutic modality).
- **A monomorphic population of lymphocytes (often with mitotic figures) in the absence of elements of peripheral blood is characteristic of lymphoma.**

Middle-aged to older ferrets are often prescribed prednisone or other steroid therapy for treatment of nonlymphomatous diseases. This may lead to difficulty in diagnosing lymphoma, as lymphocytes are highly responsive to steroids, which may mask evidence of the disease. In these cases, tissue sampling becomes even more crucial but more difficult to interpret.

### GRADE, STAGE, & PHENOTYPE

These terms are frequently used by veterinary and human oncologists, but may be poorly understood by practitioners. They correlate tumor types with biological behaviors.<sup>16</sup> Criteria for grade and stage may differ by tumor type, so the following definitions are not necessarily universal descriptive terms. Grading and staging are two very different but equally important pieces of information that can be used for evaluation of tumors.

**Grade** refers to a description of the tumor cell and is based on its microscopic appearance. Grading systems (or factors used to determine grade) are different for each tumor type, but all are evaluated upon characteristics/information, such as:

- Histologic appearance
- Degree of differentiation
- Cell size
- Mitotic indices
- Similar descriptive information.

An example of grade would be “large cell lymphoma with intermediate mitotic index and round nucleoli.”

**Stage** refers to the extent or severity of the cancer. It typically is based on the location of the primary tumor and involvement of other sites, either regional or distant. There are several staging systems used in both human and veterinary medicine; however, it is difficult to fit all tumor types into a staging system. This is particularly true for lymphoma.

**Table 1. Proposed Staging System for Lymphoma in Ferrets**

<b>Stage I</b>	Involvement of a single lymph node or single organ
<b>Stage II</b>	Multiple lymph nodes or sites on the same side of the diaphragm
<b>Stage III</b>	Generalized lymph node involvement on both sides of the diaphragm
<b>Stage IV</b>	Any of the above stages with liver or spleen involvement
<b>Stage V</b>	Any of the above with blood or bone marrow involvement

**Table 2. Secondary Staging System for Lymphoma in Ferrets**

<b>Alimentary</b>	Includes gastrointestinal tract or mesenteric lymph node(s)
<b>Mediastinal</b>	
<b>Multicentric</b>	
<b>Cutaneous</b>	
<b>Extranodal</b>	Usually atypical locations, such as eyes, kidneys, central nervous system



An example of stage would be “Stage II lymphoma–mediastinal,” which indicates involvement of multiple nodes on the same side of the diaphragm.

**Stages of Lymphoma in Ferrets**

There is no universal staging system specifically designed for ferrets. **Table 1** is a proposed staging system based on the World Health Organization (WHO) staging system, which is also generally accepted by the American College of Veterinary Pathologists (ACVP).<sup>17</sup>

There is another staging system that is sometimes used in cats that may prove valuable as a secondary staging system for ferrets. It may add information or details when used in conjunction with the above system. This system is based on the anatomic sites of the disease and is outlined in **Table 2**.

**Phenotype: B-cell or T-cell**

**Phenotype** provides a description of the cell line of origin. For example, in lymphoma, this would classify the cells as either T-cell or B-cell in origin. This information is not included in descriptions provided by most pathologists, but can be easily identified by either immunohistochemical staining or flow cytometry.<sup>8,18</sup> Clinicians can request this information from their pathologist, generally for a nominal charge. Information regarding phenotype is increasingly important and may be the most valuable prognostic indicator for ferrets.

**INFORMATION NEEDED FOR DIAGNOSIS**

In human medicine, both grade and stage are used to plan appropriate treatment and provide a prognosis. In addition; grade and stage:

- Evaluate and compare results of different treatment protocols
- Help identify clinical trials that may be beneficial to a patient
- Provide a standardized terminology for use when collecting and assessing data, either in prospective or retrospective studies
- Enable collaboration among multiple institutions.

In ferrets, there is a lack of consistency in the literature regarding grade and stage. This makes comparing data extremely difficult. For example, although several retrospective studies discuss lymphoma in ferrets as small or large cell, their criteria for defining small versus large are not standardized, making it impossible to identify commonalities in tumor behavior or prognosis. As more diagnostic tools become readily available, we hope to identify commonalities in tumor type, which will ultimately lead to better treatment and prognosis for our patients.

**SUMMARY**

Lymphoma in ferrets is a multicentric disease with variable clinical presentations. It can be difficult to identify because clinical signs are nonspecific.

- Lymphocytosis is not a common finding; anemia is far more common but less specific.
- Mesenteric lymphadenopathy is a common but nonspe-

cific finding in many ferrets with lymphoma.

- Lymph node aspirates may be unreliable; biopsy is always preferred.
- Whenever samples are obtained, it is essential that stage, grade, and phenotype are defined to facilitate education about prognosis and treatment options for ferrets. ■

**References**

1. Erdman SE, Brown SA, Kawasaki TA, et al. Clinical and pathologic findings in ferrets with lymphoma: 60 cases (1982-1994). *JAVMA* 1996; 208(8):1285-1289.
2. Erdman SE, Moore FM, Rose R, Fo JG. Malignant lymphoma in ferrets: Clinical and pathological findings in 19 cases. *J Comp Path* 1992; 106:37-47.
3. McCalla TL, Erdman SE, Kawasaki TA, et al. Lymphoma with orbital involvement in two ferrets. *Vet Comp Ophthalmol* 1997; 7(1):36-38.
4. Erdman SE, Reimann KA, Moore FM, et al. Transmission of a chronic lymphoproliferative syndrome in ferrets. *Lab Invest* 1995; 72(5):539-546.
5. Erdman SE, Kanki PJ, Moore FM, et al. Clusters of lymphoma in ferrets. *Cancer Invest* 1996:225-230.
6. Batchelder MA, Erdman SE, Li X, Fox JG. A cluster of cases of juvenile mediastinal lymphoma in a ferret colony. *Lab Anim Sci* 1996; 46(3):271-274.
7. Coleman LA, Erdman SE, Schrenzel MD, Fox JG. Immunophenotypic characterization of lymphomas from the mediastinum of young ferrets. *Am J Vet Res* 1998; 59(10):1281-1286.
8. Onuma M, Kondo H, Ono S, et al. Cytomorphological and immunohistochemical features of lymphoma in ferrets. *J Vet Med Sci* 2008; 70(9):893-898.
9. Ammersbach M, DeLay J, Caswell JL, et al. Laboratory findings, histopathology, and immunophenotype of lymphoma in domestic ferrets. *Vet Pathol* 2008; 45(5):663-673.
10. Li X, Fox JG, Erdman SE, et al. Cutaneous lymphoma in a ferret (*Mustela putorius furo*). *Vet Pathol* 1995; 32(1):55-56.
11. Rosenbaum MR, Affolter VK, Osborne AL, et al. Cutaneous epitheliotropic lymphoma in a ferret. *JAVMA* 1996; 209(8):1441-1444.
12. Antinoff N, Hahn K. Ferret oncology: Diseases, diagnostics, and therapeutics. *Vet Clin Exot Anim* 2004; 7:579-625.
13. Antinoff N, Williams B. Neoplasia in ferrets. In Carpenter J, Quesenberry K (eds): *Ferrets, Rabbits, Rodents: Clinical Medicine and Surgery*, 4th ed. Philadelphia: Elsevier, 2011, in press.
14. Paul-Murphy J, O'Brien RT, Spaeth A, et al. Ultrasonography and fine needle aspirate cytology of the mesenteric lymph node in normal domestic ferrets (*Mustela putorius furo*). *Vet Radiol Ultra* 1999; 40(3):308-310.
15. Hanley CS, Wilson GH, Frank P, et al. T cell lymphoma in the lumbar spine of a domestic ferret (*Mustela putorius furo*). *Vet Rec* 2004; 155:329-332.
16. Vezzali E, Parodi AL, Marcato PS, Bettini G. Histopathologic classification of 171 cases of canine and feline non-Hodgkin lymphoma according to the WHO. *Vet Comp Oncol* 2009; 8(1):38-49.
17. WB Morrison. *Lymphoma in Dogs and Cats*. Jackson, WY: Teton NewMedia, 2005.
18. Hammer AS, Williams B, Dietz HH, et al. High-throughput immunophenotyping of 43 ferret lymphomas using microarray technology. *Vet Pathol* 2007; 44(2):196-203.



**Natalie Antinoff, DVM, Diplomate ABVP (Avian), practices at Gulf Coast Avian and Exotics, which she opened in 1997 as part of Gulf Coast Veterinary Specialists. The practice allows collaboration with many exotic pet specialists. She has authored chapters in several texts, lectures nationally and internationally, and is a consultant for the Veterinary Information Network Small Mammal Board. Dr. Antinoff received her DVM from University of Wisconsin–Madison; then she completed a small animal internship and residency in exotic pet medicine and surgery at The Animal Medical Center in New York City.**